

Non-Ablative Laser Treatment for Rosacea

Pedro Rolando López Rodríguez^{1*}, Lázaro Pérez Rodríguez M² and Lic M Mercedes Gil García³

¹First and second-degree specialist in General Surgery and Specialist in Aesthetic Medicine, Medical Laser Assistant Professor, Assistant Researcher and Consulting Professor, Spain

²Specialist in Laser Medicine and phototherapy in dermo-aesthetic pathologies and researcher in the development of different dermatological and vascular lesions with the use of lasers, Spain

³Lic. M in general genetic engineering and mainly in viruses and bacteria, Spain

*Corresponding author

Pedro Rolando López Rodríguez. Address: Miguel Indurain 3B, Ptal. 2, 2A. 19200. Azuqueca de Henares. Guadalajara. Castilla La Mancha, Spain.

Received: October 24, 2025; **Accepted:** November 01, 2025; **Published:** November 08, 2025

ABSTRACT

Rosacea is a chronic inflammatory dermatosis that primarily affects the midface (cheeks, nose, chin, forehead), although it can also affect other areas of the body such as the scalp, neck, auricle, chest, and eyes. Objective. To describe the clinical characteristics of a patient with extensive rosacea injuries on her skin and their possible treatment with nonablative lasers. Clinical case: Observational study in a 62-year-old patient with a dermatological diagnosis of rosacea, who was treated with nonablative lasers with excellent results, leaving no scars and resolving the injuries in just five sessions. Conclusions: Rosacea is a benign dermatological injury, and treatment with nonablative lasers is effective, leaving no scars and requiring no additional treatments.

Keywords: Rosacea, Erythematous-Telangiectatic Rosacea, Nonablative Lasers

Introduction

Rosacea is a chronic inflammatory dermatosis that primarily affects the midface (cheeks, nose, chin, forehead), although it can also affect other areas of the body such as the scalp, neck, auricle, chest, and eyes [1]. It is a common skin disease in adults that presents with various clinical manifestations. Given the wide range of signs and symptoms it includes, diagnosis has not always been easy. With the exception of ocular rosacea, it is a disfiguring disorder that is not serious [2].

Of rosacea in fair-skinned individuals ranges from 2% to 22%. Caucasian individuals with sun-sensitive skin (phototypes I and II) are at higher risk of developing rosacea; however, this condition may be underreported in individuals with skin phototypes V or VI due to the difficulty in identifying redness and telangiectasias in darker skin. Rosacea is more common in women than in men, except in the case of phymatous rosacea. The disease usually manifests after the age of 30. In a general hospital in Lima, Peru, rosacea was found to constitute 1.97% of

dermatological diagnoses, although the subtypes of the disease were not specified.

The exact pathogenesis of rosacea remains unknown, and no specific risk factors have been identified. However, several potential triggers and aggravating factors have been identified, including sun exposure, heat, spicy food, alcohol abuse, emotional state, depression, and migraine. Currently, the National Rosacea the National Rosacea Society (NRS) is revising the classification and diagnosis of rosacea. Four subtypes have been defined based on clinical patterns: subtype 1 (erythematotelangiectatic), subtype 2 (papulopustular), subtype 3 (phymatous) and subtype 4 (ocular). The prevalence of these subtypes is difficult to determine precisely, as subtypes 1 and 2 may overlap. Phymatous rosacea (subtype 3) is rare and primarily affects men, while the ocular subtype (subtype 4) is difficult to assess due to the lack of clear diagnostic criteria, with a reported prevalence ranging from 6% to 58% [3].

Regardless of the severity of the skin condition, rosacea is one of the few dermatoses associated with ocular morbidity such as red eye, foreign body sensation, tearing, photophobia,

Citation: Pedro Rolando López Rodríguez, Lázaro Pérez Rodríguez M, Lic M Mercedes Gil García. Non-Ablative Laser Treatment for Rosacea. Open Access J Clin Images. 2025. 2(4): 1-4. DOI: doi.org/10.61440/OAJCI.2025.v2.23

blepharoconjunctivitis, and corneal complications. Previously considered a skin-limited disorder, rosacea is now known to be associated with systemic disorders including those of the respiratory tract (asthma and chronic rhinosinusitis), gastrointestinal system (gastritis, gastroesophageal reflux disease), metabolic disease (obesity, hypertension, and diabetes), hepatobiliary system disorders (hepatitis and others), and migraine [3]. Rosacea has been reported to have the potential to cause molecular changes in distant body fluids, including oral cavity fluids, further reinforcing the systemic impact of the disease [4].

The need for a better understanding of rosacea is evident, given its impact not only on the skin but also on other body systems, underscoring the importance of a multidisciplinary approach to its management. Despite advances in the classification and diagnosis of rosacea, significant gaps in knowledge persist regarding its pathogenesis and the effective management of its various subtypes. Technology, such as the use of lasers and intense pulsed light, has been shown to be effective in improving erythema and telangiectasias, complementing topical and systemic treatments. These advances allow for more effective and aesthetic management of the disease, but also highlight the need for continuous and personalized treatment due to the chronic nature of rosacea [5].

Therefore, this literature review aims to address current clinical practices and new therapeutic perspectives in the treatment of rosacea, providing a comprehensive overview based on the most recent scientific evidence. To this end, an exhaustive search and analysis of the available literature was performed in recognized medical databases, selecting relevant studies that address the identification, clinical management, and emerging therapeutic strategies in rosacea. This methodology will allow a deeper understanding of the disease and the identification of critical areas that require attention in future research and clinical practice.

Method

An observational study was conducted in a case diagnosed and treated with Rosacea on the face. The patient's medical history was reviewed in detail and the clinical method was appropriately applied, which allowed the necessary data to be collected for the interview and physical examination. Diagnostic and therapeutic measures were used, including: the search for dermatological evidence, analysis and use of the XEO equipment, a Genesis Non-Ablative laser handpiece with a programming of: Fluence 14 J/cm², pulse duration 0.3 ms, repetition frequency 7 Hz and spot size 5 mm and the following sessions 15 J/cm², pulse duration 0.3 ms, repetition frequency 10 Hz. In all sessions, 8,000 pulses were applied in each session of the applied treatment, with good tolerance and comfort, without the need for topical anesthesia.

Clinical Case

A 62-year-old Caucasian female patient attended WAAS Medical Center in Madrid, complaining of facial itching caused by reddened lesions in several areas.

Physical examination revealed reddened lesions of various shapes and irregular circular sizes, 1-2 years old.

A dermatological study was performed, which confirmed the diagnosis of Rosacea, which were benign lesions.

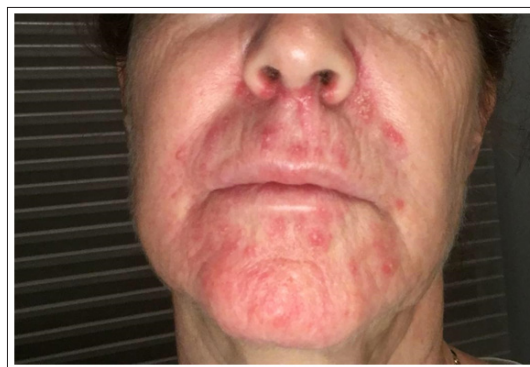

Figure 1: Patient's Rosacea Lesions

This lesion was treated with a 1064 nm neodymium YAG laser. XEO, with a programming of 14 J/cm², 0.3 milliseconds, 7 Hz and 5 mm. And 15 J/cm², 0.3 milliseconds, 10 Hz and 5 mm. 8,000 pulses are administered per session, it does not require anesthesia, it is painless and is performed on an outpatient basis, allowing the patient to return to work without days off. The results are obtained with the disappearance of the lesions in just five sessions, leaving no scars or recurrence. It does not require surgery, nor does it entail high costs and loss of days of activity for the patient and their family, in addition to the discomfort derived from possible complications. The real advantages that we offer in the treatment of these lesions with the application of the non-ablative laser in our center are evident

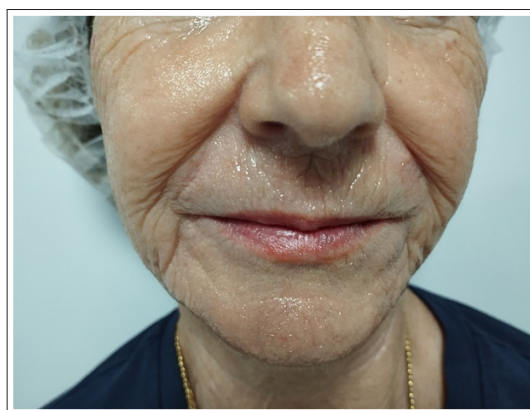


Figure 2: Result of Non-ablative Laser Treatment

Discussion

The epidemiological characteristics of rosacea vary widely according to population and geographic area. In Europe, several studies on the prevalence of rosacea have been conducted; however, it has been reported to vary between 2% and 10% [6,7]. This study found that more women than men had rosacea, which is consistent with previous findings [8]. Furthermore, it was found that there was no gender predominance in prevalence, unlike what has been reported, which indicates a predominance of rosacea in women. Moreover, it has been reported that rosacea is more prevalent in people whose age is found between the fourth and fifth decades of life [7,8]. However, in the sample of this study, the most common age of onset of the disease was the sixth decade of life. However, the prevalence varied according to sex: in male patients, the age of onset

The disease was consistent with what has been reported so far, while women showed symptoms from an earlier age, being more frequent between 20 and 30 years old, and between 50 and 60 years old. In this study, the mean age was 49 years, similar to that reported in another study carried out on Colombian patients. 8 We also found that 1 in 20 individuals was under 20 years old, which reveals a relevant finding for future studies aimed at to younger populations with the disease. The average duration of rosacea symptoms was over 3 years, which could be because they are not severe or because people do not consider its signs and symptoms a disease and may have become accustomed to them.

This study showed that the most affected phototypes were III and IV, representing almost half of the population, which is striking when considering

Consider the results of different studies in which light skin phototypes (I and II) are most frequently affected. However, this could be linked to the fact that the signs of rosacea, especially erythema, go unnoticed in individuals with phototypes [9].

Regarding rosacea subtypes, the literature describes a wide variability in the frequencies of manifestation: erythematous-telangiectatic rosacea varies between 12 and 78%, papulo-pustular rosacea between 22 and 69%, the phymatous subtype between 0.7 and 6%, and the ocular subtype between 1 and 72%. 8,15,16 Some authors state that erythematous-telangiectatic rosacea is the most frequent subtype, while others state that it is the papulo-pustular form [10]. Similar to reports from Colombia, in this study we found that the frequency of erythematous-telangiectatic rosacea was twice that of papulopustular rosacea, while the phymatous and ocular subtypes had low frequencies. 8 We found that more men manifested the phymatous subtype, which could be due to the higher concentrations of androgens and their role in inflammation in this population. 11 Furthermore, we believe that because rosacea is one of the most underdiagnosed conditions, the percentages of each subtype described in the different studies may be underestimated. Regarding comorbidities in patients with rosacea, a relationship with cardiovascular diseases has been described due to the chronic inflammation present in both conditions [11].

Furthermore, the probable relationship with gastrointestinal and psychiatric comorbidities has gained great relevance in recent decades, explained from the concept of the gut-brain-skin axis. It has been proposed that the increased expression of substance P is involved in the pathophysiology of rosacea and other skin diseases that may have chronic inflammation and intestinal dysbiosis in common [12-14]. Other authors suggest that this association is likely due to immunoendocrine interactions and a possible interaction with autoimmune thyroid antibodies [15]. In this study, it was found that hypothyroidism was the second most frequent comorbidity after high blood pressure, affecting more than 1 in 10 patients. Likewise, the relationship of atopic conditions in patients with rosacea has been studied; however, to date, no statistically significant association has been found [16]. Furthermore, the influence of epithelial barrier function and atopic diathesis has been evaluated in various dermatoses, including rosacea, without finding a direct influence on the onset or severity of rosacea [17]. Furthermore, in order to address the diagnosis of this disease from primary care, we

consider it necessary to implement educational strategies for health personnel. From primary care levels and for the general population to promote timely consultation and treatment [18-20].

Conclusions

Rosacea is a benign dermatological lesion, and its treatment with non-ablative laser is effective. The lesions disappear in just a few sessions, it leaves no scar, requires no anesthesia or surgery, and is performed on an outpatient basis, allowing the patient to resume normal activities.

Conflict of Interest

The authors declare that they have no conflicts of interest.

Reference

1. Gil Diaz MJ, Boixeda de Miguel JP, Thuchuelo Diez M, Mora Cardosa P. Rosacea : Review and new therapeutic alternatives. *Med Fam Semerg*. 2011. 37: 83-86.
2. Rangel A, Rodriguez K, Ruz H, Calderon J. Impact of nutrition on rosacea. *Narrative review. Rev Group Inv Com Salud*. 2024. 9: 415-422.
3. Cordero Romero P. Rosácea: present and future. *More Dermatol*. 2025. 50.
4. San Lucas Guadalupe AK, Pinos Reyes BF, Rivera Ticona AA, Fernandez Ordaz AR. Rosacea. Identification, clinical management, and new therapeutic perspectives. *Rev. Reciamuc*. 2024. 8: 282-292.
5. Berna Rico E, Lluch Gálceras JJ, Perez Garcia B, Naharro Rodriguez H, Azcárraga Llobert C, Company Quiroga J, Boixeda P. Effectiveness and safety in rosacea of a new 532 nm and 1064 nm laser device with variable sequential pulsation. *Actas Dermo-Sifiliograficas*. 2025. 116.
6. Barco D, Aloma A, Rosácea. *Acta Dermo-Sifiliografica*. 2008. 99: 244-256.
7. Awad N, Hetzel JD, Bhaipalan V, Nesto MS. Stasis dermatitis: pathophysiology current. Treatment paradigms, and the use of the flavonoid diosmin. *J Clin Aesthet Dermatol*. 2024. 17: 15-23.
8. Nicholas A, Spraul A, Fleischer AB Jr. Prescriber Phenotypes: Variability in topical Rosacea treatment patterns among united states dermatologists. *J Clin Med*. 2024. 13: 62-75.
9. Geng RSQ, Soad SPinedas, Hua N, Chen JSibbald RG, Sibbald C. Efficacy of treatment in reducing inflammatory lesion coeust in rosacea: a systematic review. *J Critan Med Surg*. 2024. 28: 352-359.
10. Desai SR, Baldwin TT, Del Rosso JQ, Gallo RI, Bhatia N, Harper JC, et al. Microencapsulated beazoyl peroxide for rosacea in context: a review of the current treatment landscape. *Drug*. 2024. 84: 275-284.
11. Martinez Zuñigas DM, Garcia Cruz S, Pinedas Muñoz M, Fandiño Ridtíguez P, Delgado Lopez G. Clinical and sociodemographic characterization of Rosacea in an IPS in Manizales. *Rev Assoc Columbus Dermatol. Cir Dermatol*. 2025. 33: 14-25.
12. Kauth M, Trusova OV. Topical ectoine application in children and adults to treat inflammatory diseases associated with an impaired skin barrier: a systematic review. *Dermatol Ther (Heidelberg)*. 2022. 295-313.
13. Algarin YA, Palimati A, Joalouk D, Tan J, Noara K. The role of vitamin D and nutrients in Rosacea. *Arch Dermatol Res*. 2024. 36: 142-146.

14. Zhai Q, Cheng S, Lose R, Xie J, Han X, et al. Metaanalysis of the efficacy of intense pulsed light and pulsed-dye laser therapy in the management of rosacea. *J Cosmet Dermatol*. 2024. 23: 3821-3827.
15. Montesino C, Reyes A, Maria C, Garcon C, Ruiz C, et al. Case Clinical case of a patient with Rosacea. *Rev. Sanit Research (Internet)*. 2024. 5.
16. Martinez MF, Si Matteo MC, Stefano PC, Bujan MM, Cella E, Bocian MG, Cervini AB. Rosacea oculocutaneous: a retrospective study in a pediatric hospital. *Rev Dermatol Argent*. 2023. 29: 108-12.
17. Miñoz Angulo R, Fierro Lozada JN, Rodriguez JD, Sanchez Zapata MJ, Castillo Medina D. Epidemiological characteristics of patients with Rosacea in a Colombian population. *Rev Dermatol Mex*. 2024. 69: 161-68
18. Chang J, Wang Y, Sun D, Zhang L, Man MQ, Tu V, et al. Characterization of rosacea in Chinese: An analysis of 254 cases. *J Cosmet Dermatol*. 2021. 20: 3666-3671
19. Husein-Elahmed H, Steinhoff M. Laser and light based therapies in the management of rosacea: An updated systematic review. *Lasers Med Sci*. 2021. 36: 1151-1160
20. Holbring C, Augustin M, Kirsten N, Mohr N. Epidemiology of rosacea in a population-based study of 161 269 German employees. *Int J Dermatol*. 2022. 6.